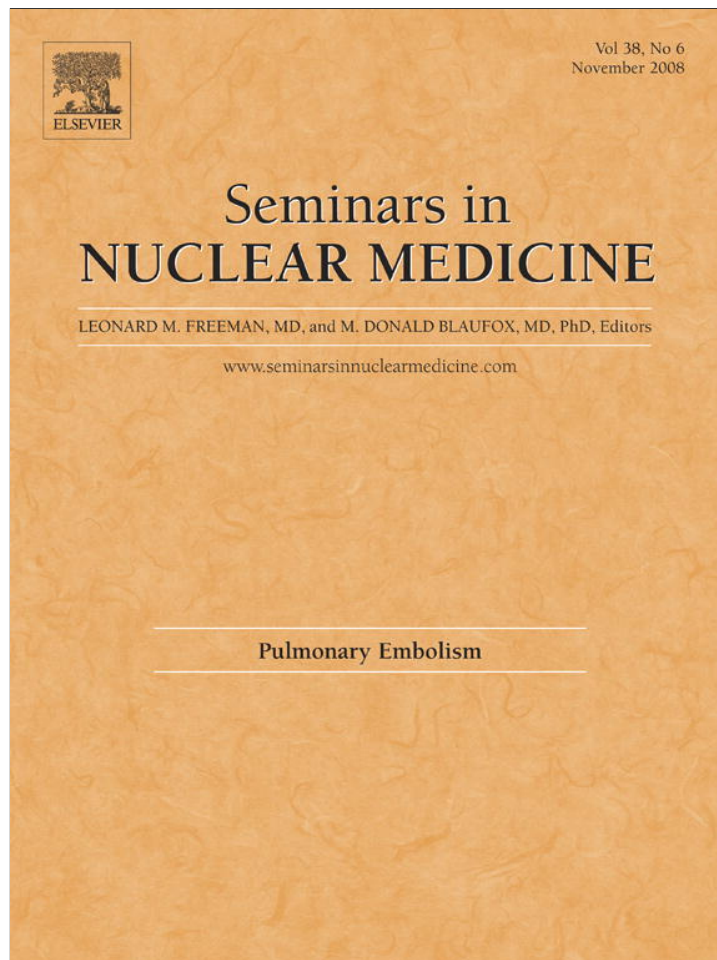


Provided for non-commercial research and education use.
Not for reproduction, distribution or commercial use.



This article appeared in a journal published by Elsevier. The attached copy is furnished to the author for internal non-commercial research and education use, including for instruction at the authors institution and sharing with colleagues.

Other uses, including reproduction and distribution, or selling or licensing copies, or posting to personal, institutional or third party websites are prohibited.

In most cases authors are permitted to post their version of the article (e.g. in Word or Tex form) to their personal website or institutional repository. Authors requiring further information regarding Elsevier's archiving and manuscript policies are encouraged to visit:

<http://www.elsevier.com/copyright>



The Current and Continuing Important Role of Ventilation-Perfusion Scintigraphy in Evaluating Patients With Suspected Pulmonary Embolism

Leonard M. Freeman, MD, Evan G. Stein, MD, PhD, Seymour Sprayregen, MD, Murthy Chamarthy, MD, and Linda B. Haramati, MD

After the publication of the Prospective Investigation of Pulmonary Embolism Diagnosis (PIOPED) study in 1990, there was considerable controversy concerning the ventilation-perfusion (V/Q) study in regard to its low sensitivity and high number of nondiagnostic examinations when used in patients with suspected pulmonary embolism (PE). Many lessons have been learned from the PIOPED database that have greatly improved our interpretive skills in the 2 decades since the study was performed. One of the key problems negatively impacting interpretation was the predominantly inpatient population that was studied. Inpatients generally are sicker patients with abnormal chest x-rays. This factor significantly degrades V/Q interpretation. A normal chest x-ray greatly facilitates accurate interpretation of the lung scan. The emergence of computed tomography angiography (CTA) in the early to mid-1990s provided a superb new means of imaging patients with suspected PE. As this technology became more sophisticated with multidetector units, it became the procedure of choice in the great majority of medical centers. CT scanners located in or proximal to many emergency departments as well as its 24/7 availability supported this preference. Within the past 2 to 3 years, the publication of the PIOPED II study as well as some other prospective and retrospective studies have confirmed similar diagnostic accuracy for CTA and V/Q studies. Additionally, there have been several recent publications cautioning physicians about the large radiation dose associated with CTA, particularly to the female breast. Considering the great benefits of both techniques as well as their limitations, it is prudent for both clinicians and imaging physicians to develop an appropriate approach to studying patients with suspected PE. Considerations such as objective clinical assessment, D-dimer assay and the chest x-ray appearance all play significant roles in this decision-making process.

Semin Nucl Med 38:432-440 © 2008 Elsevier Inc. All rights reserved.

The introduction of perfusion lung imaging 4 decades ago was a major medical advance.¹ Before that time, there existed a large diagnostic gap between clinical suspicion and laboratory studies, including pulmonary function tests and invasive pulmonary angiography. Several publications addressed the interrelationships between perfusion lung imaging and angiography.²⁻⁵ The primary imaging instrument at

that time was the rectilinear scanner, which coupled well with the high-energy ¹³¹I-labeled to macro-aggregated albumin (MAA), which was used to assess lung perfusion. The late 1960s and early 1970s witnessed a change over to gamma camera technology and technetium-99m as the label for the MAA. In addition, the radionuclide evaluation of suspected PE was further enhanced by the introduction of ventilation studies with the radioactive gas, xenon-133.^{6,7} Subsequently, another ultra short half-lived radioactive gas, ^{81m}Kr, as well as radiolabeled particles of ^{99m}Tc-DTPA have been used for the ventilation study.

During the 1980s and 1990s, ventilation-perfusion (V/Q) imaging was the procedure of choice for studying suspected PE. The probability assessment introduced by Biello's retro-

Departments of Nuclear Medicine and Radiology, Montefiore Medical Center and the Albert Einstein College of Medicine of Yeshiva University, Bronx, NY.

Address reprint requests to Leonard M. Freeman, MD, Department of Nuclear Medicine, Montefiore Medical Center, 111 East 210 Street, Bronx, NY 10467. E-mail: lfreeman@montefiore.org

spective analysis in 1979⁸ became an integral part of our interpretive language. In the mid-1980s, a group of 6 medical centers embarked on a prospective evaluation of V/Q imaging that was known as the Prospective Investigation of Pulmonary Embolism Diagnosis, or PIOPED. The results were published in 1990 in the *Journal of the American Medical Association*⁹ and have been the focus of considerable discussion and dispute for almost 2 decades. With time, it became progressively clear that certain errors were made by the originally formulated criteria. These were subsequently modified.¹⁰ However, the PIOPED study did provide a most useful computerized database that allowed further retrospective analysis and understanding as to how to optimize V/Q interpretation, particularly in the clinical setting.^{11,12}

Problems With the PIOPED Study

Classifying the Single Segmental Mismatch (SSM) as Low Probability

Biello originally classified the SSM as being of intermediate/indeterminate probability. The PIOPED investigators decided to call this low probability. This may have been part of an attempt by the PIOPED investigators to reduce the number of intermediate or indeterminate interpretations. This decision occurred before the article by Rosen and coworkers in 1986 that clearly established it as an "intermediate finding" in that 50% of their patients with this finding had PE.¹³ Unfortunately, PIOPED's finding of a 36% incidence of PE in SSM became an important part of a credibility problem that existed for low-probability interpretations.¹⁴ Pulmonologists reported that such interpretations should be considered non-diagnostic.^{15,16} Gottschalk and coworkers¹⁰ returned the SSM to the intermediate category in their 1993 modified PIOPED criteria. In a *Journal of Nuclear Medicine* editorial, Gottschalk¹⁷ discussed why the SSM was erroneously placed in the low-probability category when the original PIOPED criteria were formulated in the early 1980s. At that time, the PIOPED investigators felt that the available data from the literature justified a low probability classification for the SSM.

Changes in Positive Predictive Value (PPV) of a Low-Probability Interpretation

Biello's original low probability interpretation carried with it a <10% PPV for PE. This level of confidence generally is acceptable to the clinician faced with the decision as to whether or not to use anticoagulants. In an attempt to cut down on the number of intermediate interpretations, the PIOPED investigators associated low-probability interpretation with a <20% PPV. This larger margin of potential error also had a significant impact on anticoagulant management decision. Clinicians managing these patients were willing to accept a possible 10% error, but 20% was considered too great a possible risk to encounter. This further eroded the credibility of low probability interpretations.¹⁴

The Majority of Subjects Were Inpatients

One of the criticisms of the PIOPED study was the very high number of intermediate or indeterminate interpretations, which constituted 39% of the total population studied (364 of 931). This is not surprising when one considers that 68% of the subjects were inpatients. These generally are sicker patients with a strong likelihood of having chest x-ray abnormalities, such as opacities, fluid accumulations, etc. These create "triple-matched" abnormalities (V, Q, and radiograph) that necessitate an intermediate interpretation. Subsequent prospective studies discussed below more appropriately focused on outpatient populations with normal or near normal chest radiographs. This, in turn, minimizes intermediate interpretations. This was another of the important lessons learned from the PIOPED study. Sostman and coworkers¹⁸ recently presented retrospective data dealing with the relative sensitivity and specificity of the PIOPED I and the subsequently performed PIOPED II study.

Lessons Learned From PIOPED

As indicated, the computerization of the study provided a very important database from which clinically useful information concerning V/Q interpretation was subsequently extracted.

Ancillary Scintigraphic Findings

Observations made before PIOPED, such as the use of the stripe sign¹⁹ as well as those made retrospectively from PIOPED, such as the fact that triple matches in the mid- and upper lung fields and large pleural effusions (without other mismatches) could appropriately be called very low instead of low or intermediate probability^{20,21} have greatly enhanced and clarified interpretation.

Freeman and coworkers summarized several other scintigraphic findings that have improved our ability to interpret V/Q studies in a previous issue of *Seminars in Nuclear Medicine*.²² Those allowing a low-probability interpretation include studies with the ventilation defect appearing worse than the perfusion abnormality.²³

Stratification of Patients

Stein and coworkers¹¹ showed that differences exist in probability assessments depending on whether underlying cardiopulmonary disorders are present or absent. A striking example of this relates to the single segmental V/Q mismatch, which in the 1993 modified PIOPED criteria, was replaced into the intermediate probability category where Biello had originally assigned it. However, Stein's work showed that in a patient with no underlying cardio-pulmonary disease, the PPV of this finding became 86%, which put it into the high probability category.

The concept of patient stratification also relates to the 68% inpatient population of PIOPED I and goes a long way to explaining its relatively poor V/Q sensitivity as compared with PIOPED II where only 11% of those studied were inpatients.¹⁸

Table 1 Wells Criteria for Objective Clinical Assessment of PE*

Clinical Features	Score (Points)
Clinical signs and symptoms of DVT (objectively measured leg swelling and pain with palpation in deep vein system)	3.0
Heart rate >100 beats/min	1.5
Immobilization >3 consecutive days (bed rest except to access bathroom) or surgery in previous 4 weeks	1.5
Previously objectively diagnosed PE or DVT	1.5
Hemoptysis	1.0
Malignancy (cancer patients receiving treatment within 6 month or receiving palliative treatment)	1.0
PE as likely or more likely than alternative diagnosis (based on history, physical exam, chest radiograph, EKG, and blood tests)	3.0

Score: ≤ 4 = low probability, ≥ 4.5 = high probability.

*Based on Wells et al²⁴ and modification.²⁵

Importance of Pretest Probability (Objective Clinical Assessment)

After PIOPED, objective clinical assessment was clearly established as one of the key ingredients in establishing a definite V/Q or CTA diagnosis. The Wells criteria have been adopted by many as a means to create more objectivity between different observers.²⁴ Although originally described as a high, intermediate, or low classification, it has more recently been dichotomized into a clear-cut high or low pretest probability assessment.²⁵ This newer classification uses scores of 4.5 or greater as high pretest probability whereas 4 or lower constitutes low pretest probability. The individual components are listed in Table 1. We have encouraged our clinicians, particularly those in the emergency department (ED) to use the Wells score. Of interest is that a recent published survey assessing pretest practices of clinicians treating patients with acute PE revealed that the great majority (72.5%) surveyed prefer an unstructured approach (as opposed to published algorithms) to estimate pretest probability.²⁶ This subjective approach works best with more experienced clinicians since most of the components used in the Wells classification become an integral part of their "gestalt" impression. However it is assessed, it is clear that objective clinical assessment plays an important role in making management decisions. A good example again relates to the single segmental mismatch. As discussed previously, its 86% PPV in the patient with no underlying cardiopulmonary disease can be increased to 100% when a high pretest probability is added to the picture.¹²

Further Refining V/Q Interpretation

The manner in which we interpret V/Q scans has improved considerably since the original PIOPED study. In addition to

the use of ancillary scintigraphic findings and correlation with patient stratification and objective clinical assessment, we have benefited greatly from Gottschalk and coworkers' work reclassifying several findings into the category of "very low probability".²⁷ These findings are listed in Table 2. The use of this very low probability category can be safely used to rule out PE, particularly when combined with a low probability clinical assessment. Other factors also have contributed to why current V/Q interpretation has improved considerably over what it was at the time of the original PIOPED study two decades ago. Table 3 summarizes these more recent considerations that allow for a very low probability interpretation.

The Emergence of CT Angiography

The development of helical CT in the early 1990s allowed the pulmonary arterial tree to be imaged during a single CT acquisition. Remy-Jardin and coworkers²⁸ in 1992 published the first series comparing CTA using single detector helical CT, with conventional catheter angiography. They and others found CT to perform well in depicting central but not subsegmental emboli.²⁸⁻³¹ However, this limitation of CT was mitigated by the fact that even catheter angiography only has a 40 to 60% interobserver reliability for the diagnosis of pulmonary embolism at the subsegmental level.³² Clinical studies showed that the negative predictive value of CTA was comparable with that of catheter angiography.^{33,34} Subsequently, CTA was widely embraced, overtaking V/Q in 2001 as the most common imaging modality for suspected pulmonary embolism.³⁵ Advances in the current multidetector CT technology have considerably improved the ability of CT to depict small, subsegmental emboli.³⁶⁻³⁹ Overall, there has been an increase in the diagnosis of pulmonary emboli since

Table 2 Criteria for a Very Low Probability of PE (<10% PPV)*

1. Nonsegmental perfusion abnormalities. These are enlargement of the heart or hilum, elevated hemidiaphragm, linear atelectasis, or costophrenic angle effusion with no other perfusion defects in either lung.
2. Perfusion defect smaller than corresponding radiographic lesion
3. >2 matched V/Q defects with regionally normal chest radiograph and some areas of normal perfusion elsewhere in the lungs
4. 1 to 3 small segmental perfusion defects (<25% of a segment)
5. Solitary triple matched defect (defined as a matched V/Q defect with associated matching chest radiographic opacity) in the middle or upper lung zone confined to a single segment.
6. Stripe sign, which consists of a stripe of perfused lung tissue between a perfusion defect and the adjacent pleural surface (best seen on a tangential view).
7. Pleural effusion equal to one third or more of the pleural cavity with no other perfusion defect in either lung.

*From Gottschalk et al.²⁷

Table 3 Improvements in V/Q Interpretation Since PIOPED I

1. The original PIOPED study had a very heavy concentration on inpatients, which constituted 68% of the total population studied. PIOPED II had an inpatient population of 11%. Inpatients are much more likely to have chest x-ray abnormalities that would potentially interfere with optimal V/Q interpretation. Screening patients with a chest x-ray has very significantly cut down the number of intermediate, nondiagnostic interpretations.
2. The use of a number of ancillary scintigraphic findings not used in PIOPED I subsequently became available to us.²² Some of these were based on data made available from retrospective review of PIOPED. Most of these allow a very low probability or PE ABSENT interpretation. These include:
 - a. The stripe sign¹⁹
 - b. The fissure sign^{69,70}
 - c. Segmental contour pattern⁷¹
 - d. Large pleural effusions with matched V/Q findings and no other V/Q mismatches²¹
 - e. Radiographic densities with matched V/Q findings in upper or mid-lung zone²⁰
 - f. Perfusion scan better than abnormal chest radiograph
 - g. V defects worse than Q defects: reverse mismatch²³
3. Stratification of patients who may or may not have underlying cardiopulmonary disease has enhanced interpretation
4. Retrospective analysis of the PIOPED criteria found errors, eg, a moderate SSM was erroneously called low probability. In a subsequent publication modifying the original criteria, the SSM was correctly placed in the intermediate category
5. Different significance of findings when correlated with objective clinical assessment (pre-test probability), ie, a SSM in a patient with high pretest probability constitutes a high probability V/Q interpretation
6. Improved particle ventilation agents are now available than can be used in place of the older, but still superb xenon-133 study. The optimal particle, inhalatory agent, TECHNEGAS (Cyclopharma Corp) has been used worldwide outside the U.S. for the past 15 years. It will, hopefully, receive approval from the Food and Drug Administration within the next year.
7. Nuclear medicine instrumentation has improved considerably. Most centers use dual headed detectors to considerably shorten the time of the examination. Those that continue to use single headed cameras have instruments with significantly better resolution than those used in PIOPED I. Very few of the cameras used in the mid-1980s for PIOPED I would be acceptable by today's standards.

In addition, the use of SPECT in many centers, primarily outside the U.S., has improved diagnosis.

the advent of CT. However, the benefit of this increased diagnosis is uncertain as the risks of recurrent thromboembolism and death have not declined.³⁹

A recent prospective study has shown relatively equivalent sensitivity and accuracy between CTA and V/Q studies.⁴⁰ Our retrospective review has shown similar results (see "Recent Studies Comparing the V/Q Scan and CTA"). Because of the greater associated radiation exposure with CTA as compared with V/Q, it is prudent to develop a strategy as to when each should be used in a particular clinical setting. The difficulties in interpreting V/Q studies are most frequent in patients with pneumonia, atelectasis, pleural fluid and severe chronic obstructive pulmonary disease. We have found the plain chest x-ray a simple means of selecting which procedure should be performed. This is discussed further later in the article.

There is one additional, important advantage that CTA offers over V/Q imaging, which is its ability to make alternative anatomic diagnoses that may turn out to be the cause of the patients' symptoms. Significant findings, such as dissecting aneurysm or pneumothorax, may be detected.³⁶ Cronin and coworkers present a thorough, detailed discussion of CTA elsewhere in this issue of *Seminars in Nuclear Medicine*.⁴¹

The PIOPED II Study

The increasing popularity and availability of CTA stimulated the PIOPED investigators to undertake what was originally anticipated to be a prospective comparison of CTA and V/Q imaging. The results of the study were published in the June

1, 2006, issue of the *New England Journal of Medicine*.³⁸ Rather than a comparative study, PIOPED II focused on the accuracy of CTA, itself. Most importantly, the results do not clearly support the superiority of CTA over V/Q scanning for the diagnosis of PE.

It is interesting to note that the V/Q scan actually represented the most frequently used reference standard required for entry into the PIOPED II study. Thus, the V/Q study became a significant part of "truth" (final decision of whether or not the patient actually had PE). Other components of the reference standards included objective clinical assessment (Wells score), venous ultrasonography for deep venous thrombosis (DVT) and, where possible, digital subtraction angiography.

The results obtained for CTA for the 824 patients studied showed an overall sensitivity of 83% (150 of 181 patients) and a specificity of 96% (567 of 592 patients). These values were calculated after patients with poor quality studies insufficient for conclusive interpretation (51 patients or 6% of the total population) were removed. If these inadequate studies were included, the sensitivity and specificity would drop to 78% and 90%, respectively. The overall PPV was 86% and the negative predictive value was 95%. These values are comparable with V/Q statistics.

Of particular interest in the study was the importance of correlating the CTA results with objective clinical assessment. When discordance existed between a low Wells score and test results, the PPV of the positive CTA was only 58%. Similar results existed for the V/Q scan in PIOPED I, where

the PPV was only 56% when this discordance existed. In fact, the final sentence of PIOPED II states that “additional testing is necessary when clinical probability is inconsistent with the imaging result.”³⁸

As with the PIOPED I study, the available computer database allowed retrospective review which Sostman and coworkers¹⁸ recently used to assess the performance of V/Q scintigraphy in the study. The composite reference standard used to judge V/Q results was either DSA or CTA results that were concordant with the Wells score. The sensitivity of a high probability scan finding was 77.4%, and the specificity of a normal or very low probability study was 97.7%. Their conclusion states that V/Q scanning “can be considered an appropriate pulmonary imaging procedure in patients for whom CT angiography may be disadvantageous.” As will be discussed, the patient population in which CTA may be considered disadvantageous is quite large due in great part to the radiation exposure associated with CTA, particularly to the female breast.

Gottschalk and coworkers²⁷ retrospective analysis of PIOPED II data using their “very low probability” criteria resulted in this interpretation being made in 56% of the patients. In these patients, the PPV was 8.2%. Furthermore, when combined with a low probability objective clinical assessment, a very low probability V/Q interpretation resulted in a very favorable PPV of only 3.1%.

Recent Studies Comparing the V/Q Scan and CTA

Canadian Study⁴⁰

An important study by Anderson and coworkers reported in December 2007 prospectively randomized patients, who were suspected of having PE, between CTA and V/Q. The suspicion was based on a high probability objective clinical assessment (Wells score of 4.5 or greater, see Table 1) or a positive D-dimer test result. Patients with DVT or PE diagnosed within the prior 3 months were excluded, as were those with contraindications to contrast media. All patients with a nondiagnostic V/Q scan or a negative CTA also had leg vein ultrasonography. The study was designed so that the primary outcome was the development of either DVT or PE in the ensuing 3 months in patients in whom PE had been excluded by either the V/Q or CTA study.

Of the 712 patients randomized to V/Q, 101 (14.2%) were diagnosed with PE or DVT on the initial study whereas of the 694 patients randomized to CTA, 133 (19.2%) had positive findings. Most importantly, the 3-month follow up revealed that only 6 of 661 (1%) of the initially negative V/Q group and 2 of 561 (0.4%) of the initially negative CTA group subsequently developed either PE or DVT. This is a statistically insignificant difference.

One of the interesting comments made by these authors as well as others was whether we might actually be detecting smaller pulmonary emboli on CTA exams that might not be of clinical significance. This issue was also addressed in an accompanying editorial that suggests that we are over diag-

nosing PE.⁴² Some investigators feel that the detection of these clinically insignificant clots has unnecessarily exposed these patients to the risks of anticoagulation. It is believed that small emboli often resolve spontaneously because of the intrinsic fibrinolytic activity of the lung.³⁷ DVT does not resolve spontaneously.⁴³ Additional clinical trials with long-term follow-up are needed to appropriately resolve this important concern of whether or not smaller emboli require anticoagulation.

Montefiore Study

As at most other medical centers, the number of CTA examinations being performed for suspected PE has increased greatly over the past several years at our institution. With growing concern about the radiation exposure issue, we met with our ED physicians to try and reverse this trend. The PIOPED II data were reviewed to assure them that the procedures were diagnostically equivalent. A simple strategy was agreed on whereby the plain chest x-ray was used to determine which procedure the patient would have. Normal or near-normal radiographs had V/Q studies whereas those showing infiltrates, atelectasis, and pleural effusions had CTA. The retrospective comparison of years 2007 versus 2006 statistics showed a reversal of the prior trend with CTAs decreasing and V/Q studies greatly increasing. The number of positive V/Q studies was quite low (3.5%) as compared with CTAs (13%). The very low number of positive V/Q studies was attributable to the fact that the ED physicians were reluctant to discharge a low suspicion patient despite a negative D-dimer unless an imaging study was performed. Before 2007, this had been a CTA whereas after our meeting, the V/Q study was used. Another striking and significant result was that the FN rates on 3-month follow-up at Montefiore were an identical 1.1% for both procedures. As with the Canadian study, this was based on the development of either DVT or PE within the same time frame.

The Radiation Exposure Issue

The number of imaging studies has increased greatly during the past 3 decades. The primary concern of this trend relates to the radiation exposure associated with these studies.⁴⁴⁻⁴⁶ A recent study performed at the Orlando Regional Medical Center and the Washington, DC Hospital Center reviewed the 5-year cumulative radiation exposure that emergency department patients received from multiple diagnostic imaging procedures.⁴⁷ The average estimated effective dose was 45.0 milliseiverts (mSv) with 12% of the sample population receiving the unacceptably high dose of more than 100 mSv. Both CT scans and nuclear medicine procedures were implicated as being responsible for the most radiation. Concern was raised that a substantial number of patients may be placed at risk of developing a higher cancer risk than that of the normal population. Further concern about CT, in particular, has been raised during the past year by several publications including the one by Brenner and Hall⁴⁶ in a *New England Journal of Medicine* review article.

A recent American College of Radiology white paper⁴⁵ points out that dose calculation is a very complex issue because absorption in each organ is variable from patient to patient. In the case of chest CT, it is clear that the organ at greatest risk is the female breast. Breast radiation estimates made using 4-slice CTA vary from 20 to 60 mSv.⁴⁶⁻⁵⁰ Einstein and coworkers⁵¹ estimate that 64-slice coronary artery CTA delivers a dose of 50 to 80 mSv to the breast. This estimate was based on the concurrent use of ECG gating, which carries with it a further significant increase in radiation dose as compared with chest CTA studies performed for PE. Comparatively, a full V/Q study delivers only 0.28 to 0.9 mSv.⁵² It is difficult to ignore this enormous 65- to 250-fold difference between the 2 procedures. Average estimates place the difference as 70- to 100-fold. Another comparison can be made with a 2-view mammogram, which is associated with a 3 mSv exposure.⁴⁸ This makes the CTA radiation dose approximately 10 to 20 times greater.

Einstein's report for coronary CTA also suggests that there exists a non-negligible increase in lifetime attributable risk of breast cancer, which is 1 in 143 for a 20-year-old woman and 1 in 284 for a 40-year-old woman.⁵¹ The International Commission on Radiation Protection has reported that CT doses can exceed limits shown to result in an increase in cancer risk.⁵³ As emphasized by the ACR white paper,⁴⁵ it is the responsibility of the imaging physician to familiarize themselves with the radiation exposure risk associated with each procedure and, in turn, educate the referring physician. The choice between CTA and V/Q represents an example where diagnostically equivalent procedures can be performed depending on the clinical considerations and the chest x-ray.

Reasons For The Recent Proliferation of CT Angiography

To propose a reasonable diagnostic strategy using both V/Q and CTA, it is first necessary to convince clinicians and diagnostic radiologists that the 2 procedures have reasonably comparable accuracy. The aforementioned studies provide these necessary data. Depending on the individual clinical setting and incorporating important information, such as patient gender, whether the chest x-ray is normal or abnormal, objective clinical assessment and D-dimer results, the clinician and radiologist, together can make an informed decision as to which procedure is best for the patient. Despite this apparent logic and the knowledge of a large radiation exposure, we continue to be confronted with a worldwide preference for CTA. The reasons for this appear to be a combination of 2 factors. These are the easier availability of the CT study and the relative expertise and confidence of the radiologists interpreting the 2 studies.

Relative availability of CTA and V/Q Imaging

In a busy ED, it is important to triage patients rapidly to determine whether hospitalization or discharge is indicated.

The patient who presents with signs and/or symptoms of possible PE often poses a diagnostic dilemma. Even in light of a low Wells score (and even a negative D-dimer), an ED physician (particularly one with less experience) feels much more comfortable discharging a patient if he or she is able to obtain a negative confirmatory imaging study. Although an unlikely occurrence, they are concerned about the possibility of sending a patient home to face an ever-existent life-threatening event. The great majority of medical centers now have CT scanners located in close proximity to the ED and x-ray technologists available on premises 24 hours a day. CTA, therefore, becomes the easier choice.

Nuclear medicine services are available on evenings and weekends in relatively few institutions because the volume of work does not financially justify an on-site or on-call technologist. This lack of availability of V/Q studies is often the major determining factor that leads clinicians to order a CTA rather than a V/Q study. Even when available, a request for a V/Q study after regular working hours requires calling in a technologist to prepare the radiopharmaceutical before performing the study. At Montefiore Medical Center, we have effectively dealt with this problem for many years. We have an on-site technologist until midnight during the week and from 9 AM to 3 PM on Saturday and Sunday. This is justifiable because we average 3 to 5 emergency studies a night. Besides lung scans, this includes hepatobiliary studies for acute cholecystitis, and gastrointestinal bleeding exams. In institutions in which scintigraphy is not available at night, another approach is feasible. In patients with a high pretest probability of PE where CTA is not desirable (particularly young women), it is suggested that temporary treatment with a single dose of low molecular weight heparin be considered. This dose is considered relatively harmless and is effective for 6 to 8 hours until a V/Q study is performed in the following morning.

Expertise of Radiology and Nuclear Medicine Residents and Attending Physicians in Interpreting V/Q Studies

Most practicing diagnostic radiologists do not feel as comfortable interpreting nuclear medicine studies as compared with other areas of diagnostic imaging that they encounter. After their residency, they enter fellowships and, subsequently, join practices that do little or no radionuclide imaging except, at this time, possibly positron emission tomography/CT. Certainly, lung scanning is not a procedure that many young practicing radiologists deal with very often. The further away they are from their residency, the less comfortable they feel with interpreting V/Q studies and the more comfortable they feel with CT imaging, including CTA. Clearly, this is an important factor as to why most chest radiologists and body imagers, in general, encourage the use of CTA rather than V/Q when assessing what to recommend when studying patients with suspected PE. In fact, there are some hospitals in this country that have completely given up on performing radionuclide lung scans. This is most unfortunate and this trend should be reversed, particularly as phy-

sicians become increasingly educated about the radiation exposure from CTA.

The practice at Montefiore is quite different in that we strongly feel that the known diagnostic equivalence of the V/Q and CTA as well as concern for the general overuse of CTA and its associated radiation exposure should make one more judicious in selecting the appropriate study. As outlined above, our use of the plain chest radiograph as our primary triage tool has proved to be successful in managing patients in a busy ED. Considerable time is devoted to teaching our residents how to appropriately interpret V/Q studies.

Role of V/Q Imaging in Institutions Where CTA Remains the Primary Procedure

Despite the concern about radiation exposure with CTA, most institutions persist in minimizing the role of V/Q and many continue to use CTA as their primary (and, in some cases, only) study for suspected PE. Even in these institutions, there are some important areas where V/Q should be used.

Contraindications to CTA

These include contrast media allergy, renal insufficiency, and other possible concerns about nephrotoxicity, excessive obesity and claustrophobia.

The Pregnant Patient With Suspected PE

Although fetal radiation is felt to be relatively comparable or slightly less with CTA,^{49,54} the breast radiation issue justifies the use of V/Q rather than CTA as the primary examination in the pregnant patient. In these patients, we have used a low dose (1 mCi of ^{99m}Tc-MAA) perfusion only study. Although actual numbers have not been kept, we have likely studied more than 200 patients at Montefiore during the past 15 to 20 years using this approach. One of the authors (L.M.F.) anecdotally recalls that greater than 95% of these exams were perfectly normal. Of course, the use of a perfusion only study in association with pretest probability has been proposed by others and is, in fact, reviewed by Miniati and coworkers⁵⁵ in an accompanying article in this issue of *Seminars in Nuclear Medicine*.

The Need for Baseline Studies After Positive CTAs for PE

The resolution of PE is a very dynamic and variable process. Even when the initial diagnosis may be PE on CTA, it is beneficial to establish a baseline with a V/Q study and to serially monitor resolution or the lack thereof.⁵⁶⁻⁵⁸ If a patient subsequently presents at some future time with suspicion of a new PE, it will be much easier to distinguish new clots from older clots that may not have resolved either partially or completely.^{22,58} Although CTA findings have been described to make this distinction, it is not always easy. Results of a

European study suggest that follow-up V/Q studies beyond 3 months are unlikely to show continued clot resolution.⁵⁷

Baseline V/Q Studies in Patients With DVT

The incidence of silent PE in patients with DVT is estimated to be 38% or greater.^{59,60} If a patient with DVT has been anticoagulated and, subsequently, develops a suspicion of PE, neither a positive CTA or V/Q study will be able to judge whether the embolus occurred before or after the start of the anticoagulation. If the latter, placement of an inferior vena cava filter may be warranted. If the PE was present at the time of DVT diagnosis, continuation of anticoagulant therapy will suffice. Performing a baseline V/Q study certainly will facilitate the decision.

The Future of V/Q Imaging and Interpretation

The Language of Lung Scan Interpretation

The use of "probability" interpretations has created considerable confusion among not only clinicians⁶¹ but also imaging physicians themselves.⁶² The single biggest problem occurred when the PIOPED investigators changed the PPV of a low-probability interpretation to 20% from Biello's original 10%. Gottschalk attempted to rectify this by creating his "very low probability" category to correspond to the more credible <10% PPV (Table 2).²⁷

Another approach to enhance communication is to use a similar interpretation for both V/Q studies and CTA. All normal and very low-probability interpretations can be called "PE unlikely" whereas a high-probability interpretation can be called "PE likely." All CTA studies showing no clot in the main or lobar vessels (even if the segmental vessels were not well visualized) can be similarly called "PE unlikely." Using this scheme, Anderson and coworkers's prospective study showed similar FN rates of 0.4% for CTA and 1.1% for V/Q.⁴⁰ Of course, either study result must be correlated with objective clinical assessment to determine further management.

The Use of V/Q SPECT

During the past several years, many of our Australian and European colleagues have routinely used SPECT V/Q studies and feel that it is easier to read and more accurate than traditional planar views.^{63,64} Although the use of a full 8 view planar study has performed well, it is certainly conceivable that SPECT may add a bit more. In select situations a combined study using SPECT/CTA may be of value. A detailed discussion of SPECT V/Q imaging by Roach and his colleagues⁶⁵ may be found in this issue of *Seminars in Nuclear Medicine* following this article.

Clot Avid Agents

Another area to look forward to could be the development of "hot spot" imaging where the clot itself may have a direct affinity to pick up the radiopharmaceutical.^{66,67} This technique has had some limited success for DVT detection⁶⁸ but,

at the present time, we are not aware of any new clot-avid agent being developed to detect PE.

Conclusion

Multidetector CTA and V/Q lung scintigraphy are both excellent imaging examinations to evaluate patients with suspected pulmonary embolism. Because of the much greater radiation exposure, particularly to the female breast, associated with CTA, it is desirable to use V/Q imaging when possible. The major problem causing difficulty in interpreting V/Q studies is underlying pulmonary disease, such as pneumonia, significant atelectasis, pleural effusions, and chronic obstructive lung disease. The use of a plain chest x-ray to detect these abnormalities and, if positive, directing the patient to a CTA is an effective strategy. Most importantly, it is the responsibility of the imaging physician to be knowledgeable about the relative value and the benefit-to-risk ratio of each procedure to properly advise the referring physician.

References

1. Wagner HN, Sabiston DC, Iio M, et al: Pulmonary blood flow by radioisotope scanning. *JAMA* 187:601-603, 1964
2. Freeman LM, Zelefsky MN, Kaplan N, et al: Diagnosis of pulmonary embolism with scanning and angiographic techniques—a correlative study. *J Nucl Med* 9:394-401, 1968
3. Moser KM, Harsanyi P, Rius-Garriga G, et al: Assessment of pulmonary photoscanning and angiography in experimental pulmonary embolism. *Circulation* 39:663-674, 1969
4. Gilday DL, Poulouse KP, DeLand FH: Accuracy of detection of pulmonary embolism by lung scanning correlated with pulmonary angiography. *Radiology* 115:137-143, 1972
5. Tow DE, Simon AL: A comparative analysis of pulmonary perfusion scans with pulmonary angiograms. *Am Heart J* 92:700-706, 1976
6. Wagner HN, Lopez-Majano V, Langan JK, et al: Radioactive xenon in the differential diagnosis of pulmonary embolism. *Radiology* 91:1168-1174, 1968
7. DeNardo GL, Goodwin DA, Ravasini R, et al: The ventilatory lung scan in the diagnosis of pulmonary embolism. *N Engl J Med* 282:1334-1336, 1970
8. Biello DR, Mattar AJ, McKnight RC, et al: Ventilation-perfusion studies in suspected pulmonary embolism. *Am J Roentgenol* 133:1033-1037, 1979
9. The PIOPED Investigators: Value of the ventilation/perfusion scan in acute pulmonary embolism. *JAMA* 263:2753-2759, 1990
10. Gottschalk A, Sostman HD, Juni JE, et al: Ventilation-perfusion scintigraphy in the PIOPED study. Evaluation of the scintigraphic criteria and interpretations. *J Nucl Med* 34:1119-1126, 1993
11. Stein PD, Gottschalk A, Henry JW, et al: Stratification of patients according to prior cardiopulmonary disease and probability assessment based on the number of mismatched segmental equivalent perfusion defects: Approaches to strengthen the diagnostic value of ventilation/perfusion lung scans in acute pulmonary embolism. *Chest* 104:1461-1467, 1993
12. Stein PD, Henry JW, Gottschalk A: The addition of clinical assessment to stratification according to prior cardiopulmonary disease further optimizes the interpretation of ventilation/perfusion lung scans in pulmonary embolism. *Chest* 104:1472-1476, 1993
13. Rosen JM, Palestro CJ, Markowitz D, et al: Significance of single ventilation/perfusion mismatches in krypton-81m/technetium 99m lung scintigraphy. *J Nucl Med* 27:361-365, 1986
14. Freeman LM: The low probability V/Q lung scan: Can its credibility be restored? *J Nucl Med* 37:582-584, 1996
15. Moser KM: Venous thromboembolism. *Am Rev Respir Dis* 141:235-249, 1990
16. Hull RD, Raskob GE: Low probability lung scan findings: A need for change. *Ann Intern Med* 114:142-143, 1991
17. Gottschalk A: V/Q imaging and the diagnosis of PE: Can we shift the gray to black and white. *J Nucl Med* 35:1931-1932, 1994
18. Sostman HD, Stein PD, Gottschalk A, et al: Acute pulmonary embolism: Sensitivity and specificity of ventilation-perfusion scintigraphy in PIOPED II study. *Radiology* 246:946, 2008
19. Sostman HD, Gottschalk A: Prospective validation of the stripe sign in ventilation-perfusion scintigraphy. *Radiology* 184:455-459, 1982
20. Worsley DF, Kim CK, Alavi A, et al: Detailed analysis of patients with matched ventilation-perfusion defects and chest radiographic opacities. *J Nucl Med* 34:1851-1853, 1993
21. Bedont RA, Datz FL: Lung perfusion defects limited to matching pleural effusions: Low probability of pulmonary embolism. *Am J Roentgenol* 145:1155-1157, 1985
22. Freeman LM, Krynycky B, Zuckier L: Enhanced lung scan diagnosis of pulmonary embolism with the use of ancillary scintigraphic findings and clinical correlation. *Semin Nucl Med* 31:143-157, 2001
23. Caravallo P, Lavender JP: The incidence and etiology of the ventilation/perfusion reverse mismatch. *Clin Nucl Med* 19:571-576, 1989
24. Wells PS, Anderson DR, Rodger MA, et al: Excluding pulmonary embolism at the bedside without diagnostic imaging: Management of patients with suspected pulmonary embolism presenting to the emergency department by using a simple clinical model and D-dimer. *Ann Intern Med* 135:98-107, 2001
25. van Belle A, Buller HR, Huisman MV, and the Christopher Study Investigators: Effectiveness of managing suspected pulmonary embolism using an algorithm combining clinical probability, D-dimer testing, and computed tomography. *JAMA* 295:172-179, 2006
26. Weiss CR, Haponik EF, Diette GB, et al: Pretest risk assessment in suspected acute pulmonary embolism. *Acad Radiol* 15:3-14, 2008
27. Gottschalk A, Stein PD, Sostman HD: Very low probability interpretation of ventilation-perfusion lung scans in combination with low probability clinical assessment reliably excludes pulmonary embolism: Data from PIOPED II. *J Nucl Med* 48:1411-1415, 2007
28. Remy-Jardin M, Remy J, Wattinne L, et al: Central pulmonary thromboembolism: Diagnosis with spiral volumetric ct with the single breath hold technique—comparison with pulmonary angiography. *Radiology* 185:391-387, 1992
29. Goodman LR, Curtin JJ, Mewissen NW, et al: Detection of pulmonary embolism in patients with unresolved clinical and scintigraphic diagnosis: Helical ct versus angiography. *Am J Roentgenol* 164: 1369-1374, 1995
30. Rathbun SW, Raskob GE, Whitsett TL: Sensitivity and specificity of helical computed tomography in the diagnosis of pulmonary embolism: A systematic review. *Ann Intern Med* 132:227-232, 2000
31. Eng J, Krishnan JA, Segal JB, et al: Accuracy of CT in the diagnosis of pulmonary embolism: A systematic literature review. *Am J Roentgenol* 183:1819-1827, 2004
32. Goldhaber SZ: Multislice computed tomography for pulmonary embolism—a technological marvel. *N Engl J Med* 352:1812-1814, 2005
33. Quiroz R, Kucher N, Kipfmüller F, et al: Clinical validity of a negative computed tomography scan in patients with suspected pulmonary embolism: A systematic review. *JAMA* 293:2012-2017, 2005
34. Perrier AP, Roy PM, Sanches Z, et al: Multidetector row computed tomography in suspected pulmonary embolism. *N Engl J Med* 352: 1760-1768, 2005
35. Stein PD, Kayalli F, Olson RE: Trends in the use of diagnostic imaging in patients hospitalized with acute pulmonary embolism. *Am J Cardiol* 93:1316-1317, 2004
36. Schoepf UJ, Holzkecht N, Helmberger TK, et al: Subsegmental pulmonary emboli: Improved detection with thin-collimation multi-detector row spiral CT. *Radiology* 222:483-90, 2002
37. Goodman LR: Small pulmonary emboli: What do we know? *Radiology* 234:654-658, 2005
38. Stein PD, Fowler SE, Goodman LR, et al: Multidetector computed tomography for acute pulmonary embolism. *N Engl J Med* 354:2317-2327, 2006
39. Burge AJ, Freeman KD, Klapper PJ, et al: Increased diagnosis of pul-

- monary embolism without a corresponding decline in mortality during the CT era. *Clin Radiol* 63:381-386, 2008
40. Anderson DR, Kahn SR, Rodger MA, et al: Computed tomographic pulmonary angiography vs. ventilation-perfusion lung scanning in patients with suspected pulmonary embolism. A randomized controlled trial. *JAMA* 298:2743-2753, 2007
 41. Cronin P, Weg JG, Kazerooni EA: The role of multidetector computed tomography angiography for the diagnosis of pulmonary embolism. *Semin Nucl Med* 38:418-431, 2008
 42. Glassroth J: Imaging of pulmonary embolism. Too much of a good thing. *JAMA* 298:2788-2789, 2007
 43. Egermayer P, Town GI: The clinical significance of pulmonary embolism: Uncertainties and implications for treatment—a debate. *J Intern Med* 241:5-10, 1997
 44. Freeman LM: Don't bury the V/Q scan: It's as good as multidetector CT angiograms with a lot less radiation exposure. *J Nucl Med* 49:5-8, 2008
 45. Amis ES, Butler PF, Applegate KE, et al: American College of Radiology white paper on radiation dose in medicine. *J Am Coll Radiol* 4:272-284, 2007
 46. Brenner DJ, Hall EJ: Computed tomography—An increasing source of radiation exposure. *N Engl J Med* 357:2277-2284, 2007
 47. Bullard TB, Papa L, Smith M, et al: Cumulative radiation exposure and cancer risk from diagnostic imaging in patients presenting to the Emergency Department (abstr). *Acad Emerg Med* 15:S58, 2008
 48. Parker MS, Hui FK, Camacho MA: Female breast radiation exposure during CT pulmonary angiography. *Am J Radiol* 185:1228-1231, 2005
 49. Cook JV, Kyriou J: Radiation from CT and perfusion scanning in pregnancy (letter). *Br Med J* 331:350, 2005
 50. Task Group on Control of Radiation Dose in Computed Tomography: A report of the International Commission on Radiological Protection. *Ann ICRP* 30:7-35, 2000
 51. Einstein AL, Henzlova MJ, Rajagopalan S: Estimating risk of cancer associated with radiation exposure from 64-slice computed tomography coronary angiography. *JAMA* 298:317-323, 2007
 52. Radiation dose to patients from radiopharmaceuticals. *Ann ICRP* 28:1-126, 1998
 53. The International Commission on Radiological Protection: Managing patient dose in computed tomography: A report of the International Commission on Radiological Protection-ICRP publication 87. *Ann ICRP* 30:7-45, 2000
 54. Hurwitz LM, Yoshizumi T, Reiman RE, et al: Radiation dose to the fetus from body MDCT during early gestation. *Am J Roentgenol* 186:871-876, 2006
 55. Miniati M, Sostman HD, Gottschalk A, et al: Perfusion lung scintigraphy for the diagnosis of pulmonary embolism: A reappraisal and review of the Prospective Investigative Study of Acute Pulmonary Embolism Diagnosis methods. *Semin Nucl Med* 38:450-461, 2008
 56. Alderson PO, Dzebolo NN, Biello DR, et al: Serial lung scintigraphy: Utility in diagnosis of pulmonary embolism. *Radiology* 149:797-802, 1973
 57. Wartski M, Collignon MA: Incomplete recovery of lung perfusion after 3 months in patients with acute pulmonary embolism treated with anti-thrombotic agents: THESEE Study Group. *J Nucl Med* 41:1043-1048, 2000
 58. Gottschalk A: The chronic perfusion defect: Our knowledge is still hazy, but the message is clear. *J Nucl Med* 41:1049-1050, 2000
 59. Moser KM, Fedullo PF, Littlejohn JK, et al: Frequent asymptomatic pulmonary embolism in patients with deep venous thrombosis. *JAMA* 271:223-225, 1994
 60. Monreal M, Ruiz J, Olazabal A, et al: Deep venous thrombosis and the risk of pulmonary embolism. *Chest* 102:677-681, 1992
 61. Gray HW, McKillop JH, Bessent RG: Lung scan reports: Interpretation by clinicians. *Nucl Med Commun* 14:989-994, 1993
 62. Gray HW, McKillop JH, Bessent RG: Lung scan reporting language. What does it mean? *Nucl Med Commun* 14:1084-1087, 1993
 63. Reinartz P, Wilberger JE, Schaefer W, et al: Tomographic imaging in the diagnosis of pulmonary embolism: A comparison between V/Q lung scintigraphy in SPECT technique and multislice spiral CT. *J Nucl Med* 45:1501-1508, 2004
 64. Bajc M, Jonson B: Conventional and SPECT lung imaging, in Biersack HJ, Freeman LM (eds): *Clinical Nuclear Medicine*. New York, Springer, 2007, pp 118-137
 65. Roach PJ, Bailey DL, Harris BE: Enhancing lung scintigraphy with single-photon emission computed tomography. *Semin Nucl Med* 38:441-449, 2008
 66. Davison JM, Bridewell R, Montilla JL, et al: A novel diagnostic method for acute pulmonary embolism: Technetium-99m apcitide scintigraphy. *Ann Intern Med* 140:1936-1939, 2004
 67. Muto P, Lastoria S: Use of radiolabeled peptides to image deep venous thrombosis and pulmonary embolism. *J Nucl Med* 41:1065-1066, 2000
 68. Taillefer R, Edell S, Innes G, et al: Acute thromboscintigraphy with (99m)Tc-apcitide: Results of the phase 3 multicenter clinical trial comparing 99m Tc apcitide scintigraphy with contrast venography for imaging acute DVT. Multicenter Trial Investigators. *J Nucl Med* 41:1214-1223, 2000
 69. James AE, Conway JJ, Chang CH, et al: The fissure sign: Its multiple causes. *Am J Roentgenol* 111:492-500, 1971
 70. Gize R, Dixon M, Mishkin F: Analysis of the fissure sign. *J Nucl Med* 12:822-824, 1971
 71. Sostman HD, Brown M, Toote A, et al: Perfusion scans in pulmonary vascular/lymphangitic carcinomatosis. The segmental contour pattern. *Am J Roentgenol* 137:1072-1074, 1981